

then in fishes (6). Arsenic exposure in experimental rats has shown to produce steroidogenic dysfunction leading to impairment of spermatogenesis (7). Few recent investigations have shown that arsenic in drinking water is associated with oxidative stress (8), genotoxicity in testicular tissue of mice (9). On the other hand recent study suggests that arsenic causes testicular toxicity probably by affecting the pituitary testicular axis (10). But the dose and duration dependent effect of sodium arsenite in drinking water on testicular tissue of mice is not well established. Thus the aim of the present study was to observe the effects of 30 or 40 mg/L sodium arsenite in drinking water for 30, 45 and 60 days on the histology and spermatogenesis of the testes of mice.

MATERIAL AND METHODS

Experimental Design: Swiss albino male mice (weighing 25 ± 5 g at the initiation of the experiment) were obtained from Central Research Institute (Ayurved), Ministry of Health and Family Welfare, Kolkata. The animals were maintained at ambient temperature of $24 \pm 1^\circ\text{C}$ in 12h light/darkness cycle. Mice were allowed standardized pellets food and sterilized water *ad libitum*. Animals were mainly divided into major 3 groups:

Group I : Control, drinking water *ad libitum* only

Group II : Sodium-*meta*-arsenite (Sigma, India) dissolved in drinking water at dose level of 30 mg/L for 30, 45 and 60 days respectively.

Group III : Sodium-*meta*-arsenite dissolved in drinking water at dose level of 40 mg/L for 30, 45 and 60 days respectively.

For the experiment forty-six animals were divided equally into 7 groups i.e. control; 30mg/L for 30, 45 & 60 days (3 groups) and 40mg/L for 30, 45 & 60 days (3 groups) respectively.

Body weight and organ weight: Body weight was measured before and after the experimental period. At the end of each experimental period, the animals were scarified and testes were dissected out and weighed individually.

Histological study: The testes were fixed in Bouin's fixative, embedded in paraffin and 5 μ thick sections were stained with routine hematoxylin-eosin. Histopathological changes in the testes were examined under optical microscope.

Morphometric study: Quantitative analysis of spermatogenesis was carried out from 5 perfect transversely cut tubules at VH-stage of spermatogenesis from each testis of respective groups. The relative number of spermatogonia, resting spermatocyte, pachytene spermatocyte and step-7 spermatids per tubular cross section were quantified at 1000X magnification (11). Correction for changes in nuclear diameter was made using Abercrombie formula (12). Seminiferous tubular diameter was determined at 400X magnification by ocular micrometer. The morphometric measurement of Leydig cell nuclear diameter was done by using ocular micrometer at 600X

magnification and Leydig cell population was analyzed per square cm area from sagittal plane area of the section at same magnification (13).

Statistical analysis: The data were expressed in Mean \pm SEM and were evaluated for statistical significance with the student t test.

RESULTS

Body and organ weight:

The body weight gain was not significantly changed after arsenic exposure in both the treated groups over a period of 60 days in comparison to the control (Group I). Significant reduction in testicular weight in Group II (Arsenic with 30 mg/L) was observed from 45 days onward. But more conspicuous decrease in testicular weight was noted in Group III (Arsenic with 40 mg/L) after 30 days and significant diminution was found on day 60 (Fig. 1).

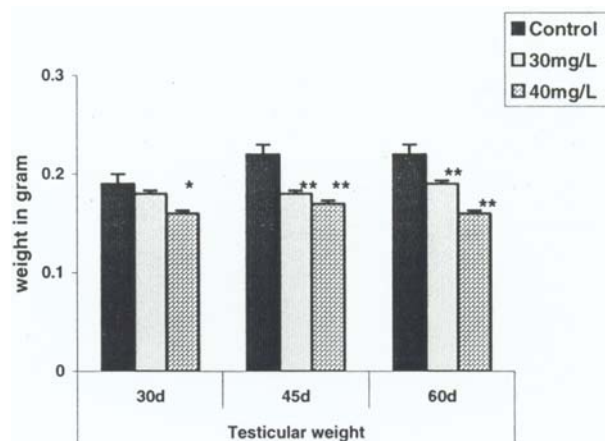


Fig. 1: Comparison of testicular weight in control and both arsenic treated experimental mice for the duration of 30, 45 and 60 days (*P<0.05; **P<0.01 as compared with respective control).

Histological finding:

Control testis (Group I) showed normal histoarchitectural organization of germ cells and Leydig cell in seminiferous tubules on day 30 through 60 (Fig. 2a, Fig. 3).

Lower dose group i.e. 30 mg/L (Group II) for 30 days showed disintegration of peritubular membrane, with disorganization of germ cells. After day 45 of Group II, vacuolization of seminiferous epithelium, loss of germ cells population along with Leydig cell atrophy were noted (Fig. 2b). In the same group on day 60, histopathological changes included degeneration and loss of germ cells, disarrangement of seminiferous epithelium and atrophy of seminiferous tubules. Leydig cell showed marked atrophy.

Treatment with 40 mg/L arsenic (Group III) produces similar effect on testicular tissue like Group II, but of higher intensity. The effect followed 30 day onward and on 45 (Fig. 2c) and 60 days. Arsenic exposure over a period of 60 days also exhibited appearance of giant cell in the seminiferous tubules (Fig. 2d, Fig. 4).

Morphometric analysis:

In Group II, spermatogonial count was not altered from that of control after 30 days through 60 days. But gradual significant decrease in resting and pachytene spermatocyte was observed in 30, 45 and 60 days respectively. The population of step-7-spermatid was conspicuously decreased from 30 day onward compared to the control in group II. Similarly in higher dose group

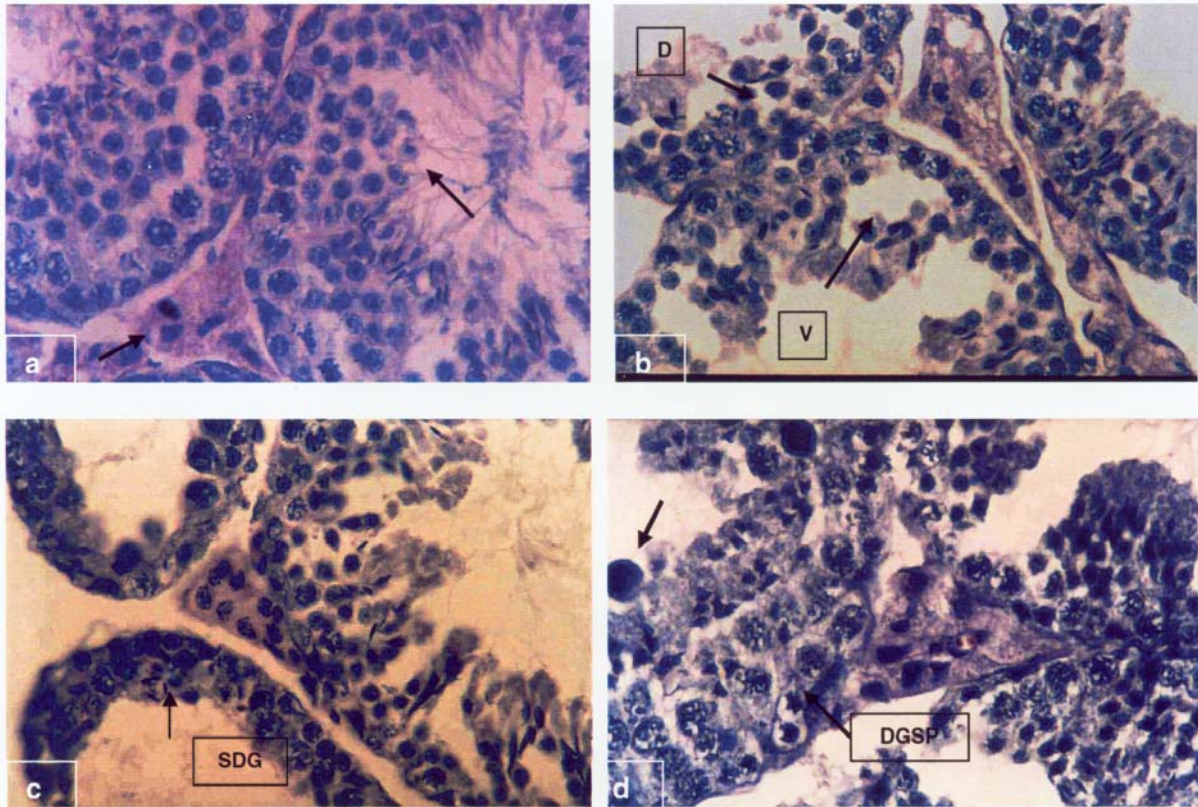


Fig. 2 : (a) Control testicular tissue in mice showing normal organization of germ cells and Leydig cell in seminiferous tubules [→]. (H & E, x 600).
 (b) Treatment with 30 mg/L arsenic on mice for 45 days showing disintegration (D) of seminiferous tubules, vacuolization of seminiferous epithelium (V) & loss of germ cells population. (H & E, x 600).
 (c) Treatment with 40 mg/L arsenic on mice for 45 days showing severe degenerative (SDG) changes in the testicular tissue where loss of germ cell is apparent in seminiferous tubule. (H & E, x 600).
 (d) Treatment with 40 mg/L for 60 days showing complete degeneration of spermatogenic (DGSP) cell with the appearance of giant cell in seminiferous tubules. (H & E, x 600).

(Group III), significant and gradual reduction in different stages of spermatogenesis i.e. resting and pachytene spermatocyte, 7-spermatid was noted after 30, 45 & 60 days but spermatogonial cell count was unaltered (Table I).

Seminiferous tubular diameter showed a dose and duration dependent reduction in both the treated groups over a period of 60 days (Table I).

TABLE I: Effect of arsenic on the testicular weight of mice.

	Testicular weight	
	Absolute weight (g)	Relative testicular weight (mg/g)
Control	0.20±0.002	5.64±0.408
30 ppm, 30 days	0.17±0.008	4.91±0.226***
30 ppm, 45 days	0.19±0.020	4.95±0.775**
30 ppm, 60 days	0.18±0.035	5.20±0.627**
40 ppm, 30 days	0.17±0.044	5.25±1.36*
40 ppm, 45 days	0.17±0.055	5.31±1.80**
40 ppm, 60 days	0.16±0.014	4.71±1.138***

Value are Mean±SEM, *P<0.001; **P<0.05; ***P<0.01.

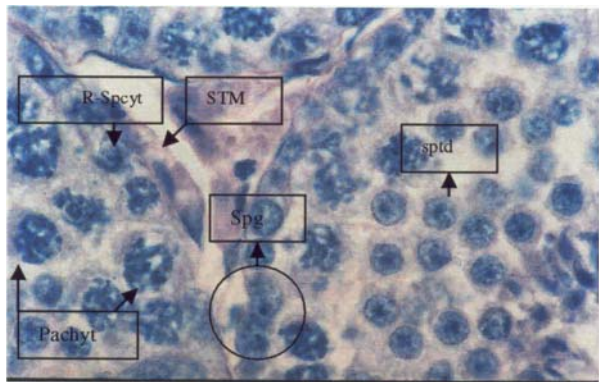


Fig. 3: Showing different germ cells in seminiferous tubules of control mice at 1000x magnification. STM: seminiferous tubular membrane, Spg: Spermatogonia, R-Spcyt: Resting spermatocytes, Pachyt: Pachytene Spermatoocytes, Sptd: Spermatids.

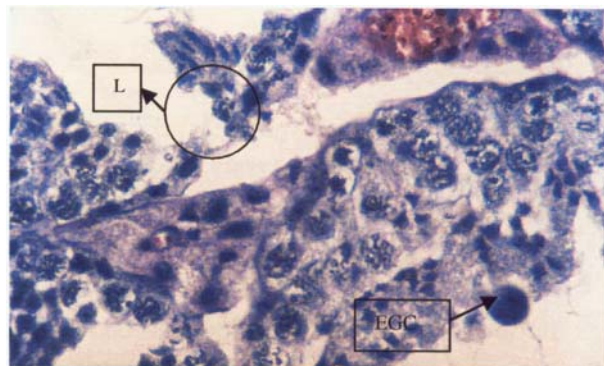


Fig. 4: Treatment with 40 mg/L for 60 days showing Leydig cell atrophy at 1000x magnification. L: Leydig cell, EGC: Eosinophilic Gaint Cell.

Gradual significant reduction in Leydig cell population compared to that of control in both the treated groups (Group II & III) over a period of 60 days was observed (Table II). The Leydig cell nuclear diameter showed a marked variation in the treated groups i.e. Group II & III. The nuclear diameter significantly increased in both the treated group initially in 30 days, but followed a slow and gradual decrease over 60 days.

TABLE II: Effect of arsenic at a dosage of 30 and 40 mg/L arsenic for 30, 45 & 60 days respectively on testicular tissue.

	Seminiferous tubular diameter (µm) [n=50]	Spermatodynamic count per 6.4 sertoli cell in each case no. of observation was 10 at the 1000x magnification			Leydig cell nuclear diameter (µm) [n=10]	Leydig cell count/cm ² [n=10]
		Spg	R-Spcyt	Pachytene (Pchyt)		
30 days						
Control	171.11±5.518	5.71±1.86	21.06±2.53	23.06±1.86	6.20±2.70	5.40±0.71
30 mg/l	168.74±3.18*	5.95±1.76 ^{NS}	19.46±3.74 ^{NS}	20.37±2.57 ^{NS}	8.73±2.84**	4.75±0.45**
40 mg/l	164.01±11.57**	5.76±1.09 ^{NS}	14.26±3.53***	17.96±2.52***	8.30±1.82*	4.48±0.48*
45 days						
Control	182.60±3.75	5.10±1.86	22.34±1.56	22.40±0.95	6.50±2.43	5.30±0.52
30 mg/l	161.87±3.20***	5.884±1.39 ^{NS}	11.51±2.96**	14.02±1.78***	5.35±1.27 ^{NS}	4.43±0.57***
40 mg/l	159.18±4.13***	5.12±1.41 ^{NS}	11.09±2.95***	13.82±2.05***	7.70±1.946 ^{NS}	4.30±0.36*
60 days						
Control	199.20±7.34	5.60±1.22 ^{NS}	23.42±2.60	23.30±2.16	6.50±2.43	5.30±0.52
30 mg/l	154.20±2.75***	5.82±1.23 ^{NS}	10.74±3.46***	10.50±3.22***	6.00±1.61 ^{NS}	4.59±0.93**
40 mg/l	157.84±4.96***	5.03±1.30 ^{NS}	10.97±3.56***	9.79±3.89***	5.57±1.27 ^{NS}	3.99±0.63*

Value are mean±SEM, ^{NS}Non significant; *P<0.05; **P<0.01; ***P<0.001; Spg: Spermatogonia, R-Spcyt: Resting spermatocytes, Pachyt: Pachytene Spermatoocytes, 7-Sptd: Spermatids. Number of observation is in parenthesis.

DISCUSSION

Arsenic is considered as a toxic metal, which reflects on human health. Various workers have observed systemic disorders (14, 15, 16), but male reproductive study in relation to arsenic toxicity is sparse. Earlier study indicated that heavy metals like lead, mercury and chromium causes cytotoxic effect in the male reproductive function (17).

Arsenic exposure to Swiss mice, in the present study, gradually decreased the testicular weight compared to control suggesting cellular regression of the testicular tissue. This observation is in corroboration with the earlier finding of Pant et al 2004 (18). Testicular histology in this study exhibited severe cellular damage in spermatogenic cell. Moreover, the appearance of eosinophilic multinucleated giant cell in the seminiferous tubule in higher treated group indicated cellular degeneration. A significant gradual dose dependent regression was observed in the number of resting spermatocyte, pachytene and round spermatid in 30 and 40 mg/L over a period of 60 days, whereas there was no significant decrease in the number of spermatogonia. These finding acts as an indicator that the maturation of spermatogonia through the process of meiosis has been severely disrupted following arsenic exposure. The above observation is in agreement with the recent finding of Omura *et al.* 2000 (19). Degeneration of interstitial (Leydig) cells was observed in the testis of arsenic-treated

mice. Moreover Leydig cell population significantly decreases in both the doses over a period of 60 days. The Leydig cell nuclear diameter increased significantly in both the doses in 30 days followed by gradual diminution of the Leydig cell diameter in 45 and 60 days. In spite of a testosterone assay in this study, it may be suggested that the degeneration of Leydig cell with significant decrease in the Leydig cell population probably would have resulted in decreased synthesis of testosterone, which in turn disturb the process of spermatogenesis. It has already been established that Leydig cell plays an important role in the structural and functional integrity of seminiferous tubules and synthesis of testosterone, which is one of the main component of regulation the post meiotic stage of spermatogenesis (20, 21, 22). The exogenous arsenic exposure may cause a chemical stress on the cellular function. The initial increase in Leydig cell diameter may be a better indication to adopt the metal induced stress but due to continuous stress effect, cellular exhaust may be a result of Leydig cell atrophy. Therefore, in conclusion, the present study revealed that arsenic induced toxicity might be responsible for testicular regression in mice.

ACKNOWLEDGEMENTS

The study was supported by grant from Defense Institute of Physiology and Allied Sciences (DIPAS). The authors wish to thank the staff of central Research Institute for taking care of the animals during the research work.

REFERENCES

1. Agency for Toxic Substances and Disease Registry (ATSDR). Toxicological profile of Arsenic. US Public Health Services, Atlanta 1993.
2. Neiger RD, OsweilerGD. Effect of subacute low-level dietary sodium arsenite on dogs. *Fund Appl Toxicol* 1985; 13: 439-451

3. Jolliffe DM, Budd AJ, Gwilt DJ. Massive acute arsenic poisoning. *Anesthesia* 1991; 46: 288-290.
4. World Health Organization. Environmental Health Criteria. 18: Arsenic. *World Health Organisation, Geneva*. 1981.
5. Pershagen G. The epidemiology of human arsenic exposure. In: Biological and environmental effects of arsenic, B.A Flower, (Ed), Elsevier, Amsterdam. 1983; 193-233.
6. Shukla JP, Pandey K. Impaired spermatogenesis in arsenic treated freshwater fish, *Colisa fasciatus* (Bl. and Sch.). *Toxicology Letters* 1984; 21(2): 191-195.
7. Sarkar M, Chaudhuri G, Chattopadhyay A, Biswas NM. Effect of sodium arsenite on spermatogenesis, plasma gonadotrophins and testosterone in rats. *Asian J Androl* 2003; 5: 27-31.
8. Chang SI, Jin B, Youn P, Park C, Park JD, Ryu DY. Arsenic induced toxicity and the protective role of ascorbic acid in mouse testis. *Toxicol Appl pharmacol* 2007; 218: 196-203.
9. Biswas R, Poddar S, Mukherjee A. Investigation on the genotoxic effects of long-term administration of sodium arsenite in bone marrow and testicular cell in vivo using comet assay. *J Environ Pathol Toxicol Oncol* 2006; 26(1): 29-37.
10. Jana K, Jana S, Samanta PK. Effects of chronic exposure to sodium arsenite on hypothalamo-pituitary-testicular activities in adult rats: possible an estrogenic mode of action. *Reproductive Biology and Endocrinology* 2006; 4:9, 1-13.
11. Leblond CP, Clarmont Y. Differentiation of stages of the cycle of seminiferous epithelium. *Ann N Y Acad Sci* 1952; 55: 548-573.
12. Ambercrombie M. Estimation of nuclear population from microtome section. *Anat Rec* 1946; 94: 239-249.
13. Chowdhury AR, Chatterjee AK. Effect of adrenalectomy on the testicular cell of immature rats. *Ind J Expt Bioll* 1978; 16: 88.
14. Tchounwou, PB, Patlolla AK, Centeno JA. Carcinogenic and systemic health effects associated with arsenic exposure. A critical Review. *Toxicol Pathol* 2003; 31(6): 575-588.
15. Guha Majumdar DN, Das Gupta J, Santra A. Chronic arsenic toxicity in West Bengal-worst calamity in the world. *J Ind Med Assoc* 1998; 96: 4-7.
16. Rossman TG. Arsenic. In: Environmental and occupational Medicine, Rom. W.N. Ed, Lippencott-Raven, Philadelphia. 1998; 1011-1019.
17. Roy Chowdhury A. Male Reproductive Toxicology-New Perspective in Life Science. In: Life Science in Modern Perspective, UGC Academic Staff College, University of Calcutta. 2004; 97-105.
18. Pant N, Murthy RC, Srivastava SP. Male reproductive toxicity of sodium arsenite in mice. *Hum Exp Toxicol* 2004; 23 (8): 399-403.
19. Omura M, Yamazaki K, Tanaka A, Hirata M, Makita Y, Inoue N. Changes in the Testicular Damage Caused by Indium Arsenide and Indium Phosphide in Hamsters during Two Years after Intratracheal Instillations. *J Occup Health* 2000; 42: 196-204.
20. Bartke A. Pituitary-Testis relationship. *Reprod Biol* 1991; 1: 136-152.
21. Steinberger E, Duckett GE. Effect of estrogen and testosterone in the initiation and maintenance of spermatogenesis in the rats. *Endocrinology* 1965; 76: 1184-1189.
22. Sharpe RM, Maddocks S, Kerr JB. Cell-cell interactions in the control of spermatogenesis as studied using Leydig cell destruction and testosterone replacement. *American Journal of Anatomy* 1990; 188: 3-20.